



A COMPARATIVE STUDY OF OCULAR SURFACE DYSFUNCTION IN INACTIVE THYROID EYE DISEASE (ITED) WITH OR WITHOUT UPPER EYELID RETRACTION

Laura G Cyrino

Renata M Maia

Lucca T Tondo

Amanda Latuffe

Suzana Matayoshi

Mario Luiz R. Monteiro

A Comparative Study of Ocular Surface Dysfunction in Inactive Thyroid Eye Disease (ITED) With or Without Upper Eyelid Retraction

Laura G Cyrino, Renata M Maia, Lucca T Tondo, Amanda Latuffe, Suzana Matayoshi, Mario Luiz R. Monteiro
University of São Paulo Medical School, São Paulo, Brazil

OBJETIVO

ITED is marked by fibrosis of the orbital tissues, exacerbating ocular surface exposure and contributing to dry eye disease (DED). While increased ocular exposure due to proptosis and eyelid retraction was once thought to be the primary cause of DED in ITED, recent research suggests that impaired tear production and inflammation may also play significant roles. However, the specific impact of upper eyelid retraction on the ocular surface in ITED patients remains understudied. This study compares ocular surface characteristics in ITED patients with (ITED-R) or without (ITED-WR) eyelid retraction.

MATERIAL E MÉTODO

This prospective study involved 106 eyes. DED was assessed using the Ocular Surface Disease Index (OSDI), invasive ocular surface assessment (TBUT, Schirmer test, fluorescein, and lissamine green staining), and noninvasive methods (meibography, tear film surface quality (TFSQ), and tear meniscus height (TMH)).

RESULTADO

There was a significant difference between ITED-R and ITED-WR groups in MGDR, Schirmer, and DMR1 (Figure 1). The ITED-R group presented higher Schirmer values than the ITED-WR group. The meibomian gland dropout ratio (MGDR) were greater in the ITED-R group compared to the ITED-WR group (Figure 2).

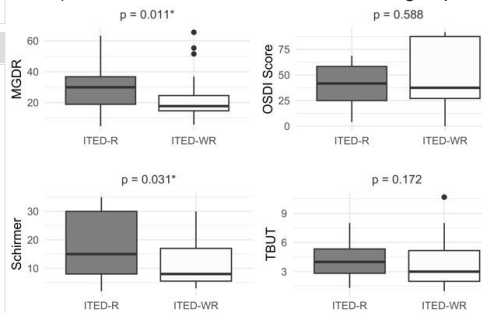
REFERÊNCIAS

- 1-Rana HS, Akella SS, Clabeaux CE, Skurski ZP, Aakalu VK. Ocular surface disease in thyroid eye disease: A narrative review. *Ocul Surf*. 2022;24:67-73.
- 2-Selter JH, Gire AI, Sikder S. The relationship between Graves' ophthalmopathy and dry eye syndrome. *Clin Ophthalmol*. 2014;9:57-62.

CONCLUSÃO

We highlight the significant role of upper eyelid retraction in exacerbating ocular surface pathology in ITED, with the presence of retraction leading to a marked increase in MGDR. Despite these objective findings, subjective symptoms (OSDI) and tear film stability (TBUT) did not show significant differences, underscoring the complex interplay between mechanical stress, inflammatory processes, and compensatory tear production in ITED-associated DED.

Figure 1. Boxplots comparing A) Schirmer; B) OSDI Score; C) TBUT, and D) MGDR between ITED-R and ITED-WR groups.



Legend: A statistically significant difference between groups was found in MGDR and Schirmer *.

Figure 2. Area of MGDR in infrared meibography used to calculate MGDR

